



PRACTICE

10-MINUTE CONSULTATION

A bleeding socket after tooth extraction

Isabelle J Moran *specialty trainee in paediatric dentistry*^{1 2}, Libby Richardson *dental core trainee*², Manolis Heliotis *oral and maxillofacial surgery consultant*¹, Alex Bewick *emergency medicine registrar*³

¹Oral and Maxillofacial Surgery, Northwick Park Hospital, London HA1 3UJ, UK; ²Barts Health Dental Hospital, London E1 1BB, UK; ³Royal London Hospital, London, UK

A fit and well 25 year old man attends his local emergency department concerned about a bleeding tooth socket after having had a lower wisdom tooth extracted earlier that morning.

Postoperative bleeding is a recognised complication after tooth extraction, with an incidence of up to 1.4% of patients undergoing lower wisdom tooth surgery.¹ It can be difficult to achieve complete haemostasis within the oral cavity because of the highly vascular nature of the tissues and exposure of the open socket to the patient's exploring tongue and fingers.²

In healthy patients, a low level ooze for 12-24 hours after extraction is normal as an organised clot forms in the tooth socket.^{2 3} The patient will have mildly bloodstained saliva that will decrease over time. Any active bleeding beyond this point often indicates a haemostatic problem and requires investigations and treatment.⁴

What you should cover

Significant, active haemorrhage must be addressed before taking a comprehensive history. It is essential to establish the degree of active bleeding and consider any predisposing factors as well as assessing how vulnerable the patient is to haemodynamic changes, such as extremes of age.

- **Factors related to the procedure** (fig 1 ↓) — Establish when the extraction took place. Did the dentist report any difficulty at the time? Contact the dentist if required.
- **Ongoing bleeding** — Find out when the bleeding began (table 1 ↓) and its nature. Is it a nuisance ooze or is the patient's mouth filling with blood after a dressing is removed?⁴ Explore whether the patient might have exacerbated bleeding by vigorous mouth rinsing or exploring with tongue or fingers.^{3 5} Has he tried simple haemostatic measures such as biting on a gauze?
- **Predisposing conditions** (box 1) — Does the patient bleed or bruise easily after trauma. Has this happened after previous extractions or surgery? Is there a history of

bleeding disorders such as haemophilia or, for females, menorrhagia in the family?⁴

- **Medical history** — Ask about bleeding disorders, reversible and irreversible medications (box 2), and chronic diseases such as leukaemia or chronic liver disease. Check the patient's alcohol consumption.^{2 4}

What you should do

Examination

Complete a primary survey and ensure that the patient is haemodynamically stable. Reassure him and explain what you are going to do.

Assess blood loss — To examine the socket, sit the patient upright under good illumination, and use suction or gauze to remove blood, saliva, and any "liver clots" (large, mobile clots resembling fresh liver, often associated with secondary haemorrhage and infection) if present. Syringing the socket with saline and use of forceps can assist this process. Is blood continually filling the mouth, or is just a sluggish ooze (fig 2 ↓) evident? Is the bleeding associated with swelling and even airway compromise?

Soft tissues — Is a high flow arterial bleed visible, or is there a tear in the gum or mucosa? Are signs of infection evident such as suppuration (pus), cellulitis and trismus, or secondary haemorrhage with liver clots?¹

Bony structures — Is bone around the socket mobile on palpation, indicating fracture? When the patient bites, do all the teeth meet? Is it very painful? Jaw fracture can occur after a lower wisdom tooth extraction, but it is rare with an incidence of 0.0049%.⁶ If fracture is suspected, refer the patient for an urgent orthopantomogram and posterioranterior view radiograph of the mandible.⁷

What you need to know

- Low level oozing from a tooth socket in the first 12-24 hours after extraction is normal
- Any active bleeding beyond this point requires investigations and treatment
- To minimise the chances of post-extraction bleeding, patients should be advised not to rinse their mouth, smoke, or undertake strenuous activity for 24 hours and to reduce contact of the socket with the tongue

Box 1: Systemic factors that increase the risk of bleeding after tooth extraction^{1 3}

- Coagulation disorders and fibrinolytic defects—for example, von Willebrand disease, liver disease (including alcohol induced liver damage)
- Platelet disorders—for example, aplastic anaemia, leukaemia
- Vascular changes or abnormalities—for example, arteriovenous malformation, collagen disorders such as Ehlers-Danlos and Marfan syndromes
- Medications (box 2) and general health complications such as hypertension

Box 2: Medications which increase the risk of bleeding after tooth extraction^{2 4}

- Antithrombotic therapy
 - Reversible—for example, warfarin, heparin
 - Irreversible—for example, aspirin, clopidogrel
- Cytotoxic medications—for example, methotrexate

Management

Be aware that patients with excessive or prolonged bleeding may vomit as swallowed blood can irritate the stomach.⁷ If you suspect a haemostatic defect from the patient's history, order appropriate laboratory screening tests such as a clotting screen, international normalised ratio (INR), and full blood count and liaise with haematology.²

Most patients will have simple slight oozing after tooth extraction, and box 3 describes how to manage these patients. Box 4 indicates when the patient should be referred.

Competing interests: We have read and understood BMJ policy on declaration of interests and have no relevant interests to declare.

Patient consent obtained.

Provenance and peer review: Not commissioned; externally peer reviewed.

- 1 Sumanth KN, Prashanti E, Aggarwal H, et al. Interventions for treating post-extraction bleeding. *Cochrane Database Syst Rev* 2016;(6):CD011930.pmid:27285450.
- 2 Hupp J, Tucker MR, Ellis E. *Contemporary oral and maxillofacial surgery*. 6th ed. Mosby, 2013.
- 3 McCormick NJ, Moore UJ, Meechan JG. Haemostasis. Part 1: The management of post-extraction haemorrhage. *Dent Update* 2014;357:290-2, 294-6.pmid:24930250.
- 4 Andersson L, Khanberg KE, Pogrel MA. *Oral and maxillofacial surgery*. John Wiley, 2010.
- 5 Brewer A, Correa ME; World Federation of Hemophilia. Treatment of haemophilia: Guidelines for dental treatment of patients with inherited bleeding disorders. 2006. www1.wfh.org/publications/files/pdf-1190.pdf.
- 6 Libersa P, Roze D, Cachart T, Libersa JC. Immediate and late mandibular fractures after third molar removal. *J Oral Maxillofac Surg* 2002;357:163-5, discussion 165-6. doi:10.1053/joms.2002.29811.pmid:11815913.
- 7 Mitchell DA. *An introduction to oral surgery and maxillofacial surgery*. CRC Press, 2005.
- 8 Joint Formulary Committee. *British national formulary*. 72nd ed. BMJ Group, Pharmaceutical Press, 2016.

Published by the BMJ Publishing Group Limited. For permission to use (where not already granted under a licence) please go to <http://group.bmj.com/group/rights-licensing/permissions>

Box 3: Management of a patient with blood oozing from a tooth socket after extraction who is haemodynamically stable

- Damp a sheet of gauze, fold into a postage stamp size, place over the socket and hold firmly in place for 5 minutes until haemostasis is established (as in fig 3¹)
- If bleeding continues, rinse the socket with saline, replace the gauze, and ask the patient to bite firmly down on it for a further 30 minutes.²
- Rarely, if oozing persists, damp gauze with 10% solution of tranexamic acid and ask the patient to bite down on it⁵ or use a mouthwash of 5% tranexamic acid³
 - Avoid if there are contraindications such as thromboembolic disease⁸
 - If tranexamic acid is unavailable, soak the gauze in saline or get the patient to bite on a damp tea bag as the tannin encourages coagulation.²
- If bleeding persists and the patient is haemodynamically stable, refer to maxillofacial team

Box 4: When should a patient be referred?

- Ensure that the patient is haemodynamically stable. Always attempt the procedures in box 2 in addition to referral.
- Haemorrhage from a soft tissue tear, fracture of the surrounding bone or jaw, or arterial bleeding—refer to the maxillofacial team
- Haemorrhage from a tooth socket of a patient with haemostatic defect or haemodynamic instability—refer to the maxillofacial and medical teams

Education into practice

- Maintenance of accurate and contemporaneous patient records can greatly improve efficiency when managing such cases. How often do you update patient family and medical histories?
- Does your department have facilities for good illumination and suction?

Patient involvement

No patients were involved in the creation of this article

Table

Table 1 | Type of postoperative bleeding after tooth extraction by time¹³

Type of haemorrhage	Time of haemorrhage	Most common cause
Primary	At time of procedure	Soft tissue and bone trauma
Reactionary	2-3 hours postoperatively	Resolution of local anaesthetic vasoconstrictor
Secondary	Up to 14 days postoperatively	Infection

Figures

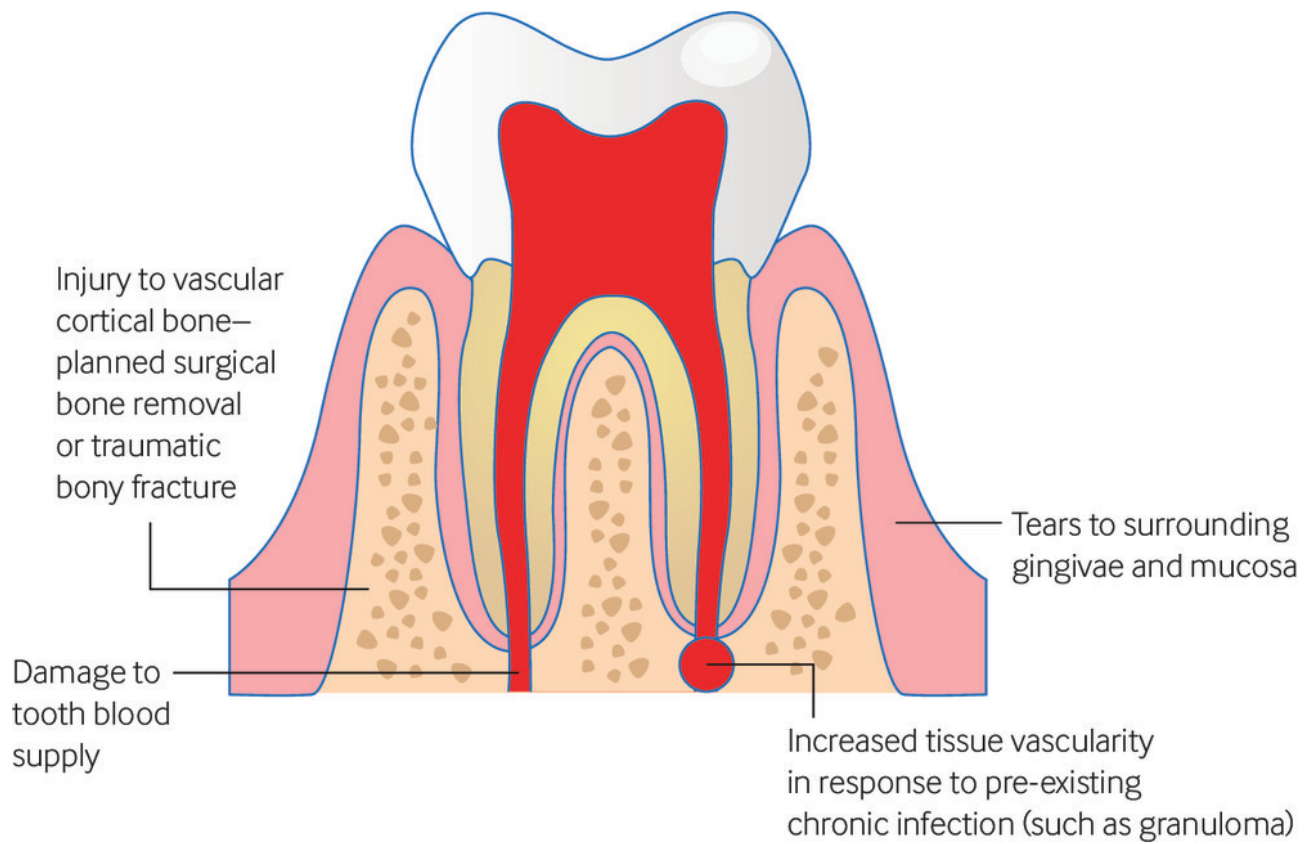


Fig 1 Local factors that can lead to postoperative haemorrhage after tooth extraction

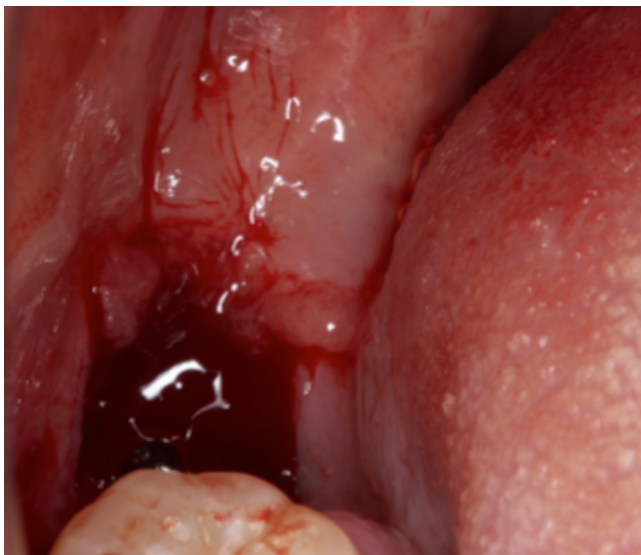

Fig 2 Generalised “ooze” from a lower wisdom tooth socket

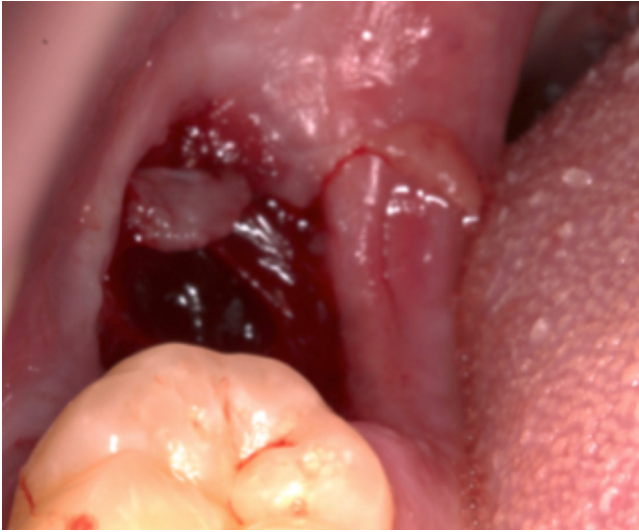

Fig 3 Established haemostasis in a lower wisdom tooth socket